

ORIGINAL ARTICLE

Histopathological Studies on Chronic Gastritis Associated with *Helicobacter pylori* Infection from Rural Area of India

Smita Bhosale¹, Basavraj Warad², Saumya Nair¹, Milind Davane³, Basavraj Nagoba^{3*}

¹Department of Pathology, ²Department of Surgery, ³Department of Microbiology, Maharashtra Institute of Medical Sciences & Research, Latur-413531 (Maharashtra) India

Abstract:

Background: *Helicobacter pylori* infection has been implicated as a major cause of chronic gastritis. It has been categorized as class 1 carcinogen. **Aim and Objectives:** An attempt has been made to evaluate the incidence of *H. pylori* in patients with chronic gastritis and to find out histopathologic indicators of presence of *H. pylori* in chronic gastritis. **Material and Methods:** A total of 101 biopsies from patients with chronic gastritis were evaluated using H & E and Giemsa stains. Biopsies were histopathologically graded according to the 1994 Updated Sydney system. **Results:** Neutrophilic activity was noted in 78 (77.2%), lymphoid aggregates were noted in 23 (22.7%) and atrophy was noted in 17 (16.83%) biopsies. The mononuclear cell infiltrate grading was mild in 43, moderate in 47 and marked in 11 biopsies. *H. pylori* were found positive in 79 (78.2%) biopsies. Neutrophilic activity with chronic gastritis and *H. pylori* association was highly significant (p value - 4.826×10^{-12}). Significant association of presence of lymphoid aggregate with chronic gastritis and *H. pylori* (p value-0.0095) was also noted. **Conclusion:** Cases with chronic gastritis associated with neutrophilic activity with presence of lymphoid aggregate suggest *H. pylori* infection. Institution of rational treatment based on accurate diagnosis and eradication of *H. pylori* significantly reduces use of acid suppression and the risk for development of gastric malignancies.

Keywords: *H. pylori*, Chronic Gastritis, Histopathologic Examination

Introduction:

Helicobacter pylori are common cause of gastritis worldwide. Besides gastritis, *H. pylori* have been implicated to cause peptic ulcer, hyperplastic

polyps, lymphocytic gastritis, anemia, peptic ulcer disease, duodenitis, intestinal metaplasia, gastric cancer and Mucosa-Associated Lymphoid Tissue (MALT) lymphoma. The diversity of clinical outcomes associated with *H. pylori* infection is probably a result of the interactions among host, environmental, and bacterial virulence factors [1].

Diagnosis of *H. pylori* can be done by both invasive and non invasive techniques. Non invasive techniques include serology, stool antigen test and carbon labelled urea breath test. The invasive techniques are rapid urease test, histology, polymerase chain reaction and *H. pylori* culture [2]. Special staining methods for detection of *H. pylori* can be used such as: Warthin-Starry; Cresyl-violet, Gimminez, Alcian yellow-toluidine blue, Genta stain, Giemsa stain and May Grünwald Giemsa [1].

The Sydney system updated in 1994 is the grading system of gastritis with which grading of gastritis can be done based on chronic inflammatory infiltrate, neutrophilic activity, lymphoid aggregate, metaplasia and presence of *H. pylori* infection using the visual analogue scale.

In the present study, an attempt has been made to evaluate the incidence of *H. pylori* in patients with chronic gastritis and to find out histopathologic indicators of presence of *H. pylori* in chronic gastritis. To the best of our knowledge this is the first report from rural area of Marathwada region of India.

Material and Methods:

The present study is a cross-sectional study conducted over a period of 1 year. In all 101 cases presenting with symptoms of dyspepsia were included in the study which showed gastritis on histopathology. From the patients with dyspepsia underwent upper gastrointestinal endoscopy using flexible fiberoptic endoscope Fujinon – EG201FP, gastric mucosal biopsies were taken and immediately transferred to a container with 10% formalin. The biopsies were then sent to histopathology laboratory. After fixation, the specimens were subjected to tissue processing. The processed tissue was then embedded in paraffin to obtain 5µ thin sections. The sections were stained with Haematoxylin and Eosin stain and Giemsa stain for parasites [3]. In gastritis cases, the histopathological grading of gastric biopsies was done using the semiquantitative method of scoring according to the Updated Sydney system using the visual analogue scale. The histopathological variables density of *H.*

pylori, neutrophil and mononuclear infiltration, atrophy and intestinal metaplasia were graded on a scale of 3 (mild, moderate and marked). Giemsa stain was used as a special stain for *H. pylori* detection. *H. pylori* colonization was assessed and graded after careful search for focal or complete involvement of the gastric surface. The sections were also examined for dysplasia or malignancy. For establishing association of different variables with incidence of *H. pylori* Chi square test and Fischer Exact test was applied.

Results:

A total of 101 biopsies with chronic gastritis were evaluated. Of these 60 biopsies were from antrum and 41 biopsies were from corpus. The mononuclear cell infiltrate grading was mild in 43 (42.57%), moderate in 47 (46.54%) and marked in 11 (10.90%) biopsies (Table1). *H. pylori* were positive in 79 (78.2%) biopsies (1+ grade of *H. pylori* in 36 (45.57%), 2+ in 25 (31.65%) and 3+ in 18 (22.80%) biopsies) (Fig.1) (Table 2).

Table 1: Histopathological Grading of Gastric Biopsies

Particulars	Mild	Moderate	Marked
Mononuclear cell infiltrate	43 (42.57%)	47 (46.54%)	11 (10.90%)
Neutrophilic activity	61 (78.2%)	15 (19.23%)	2 (2.56%)
Atrophy	15 (88.24%)	2 (11.76%)	00

Table 2: Association of *H. pylori* with Different Abnormalities

Particulars	Number of cases showing abnormalities	Number of cases showing <i>H. pylori</i>	Percentage
Mononuclear cell infiltrate	101	79	78.2
Neutrophilic activity	78	73	93.58
Lymphoid aggregate	23	23	100
Atrophy	17	14	82.35

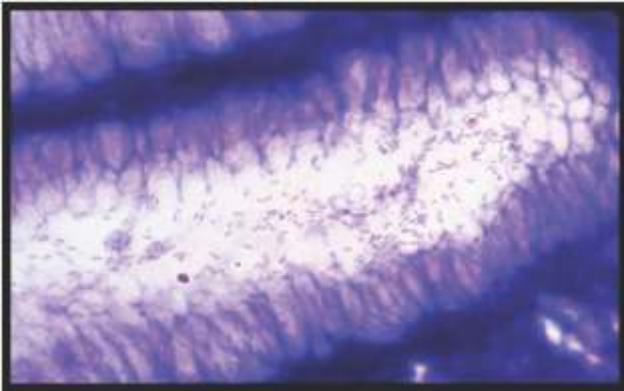


Fig. 1: *H. pylori* Grade 3 + Giemsa stain (100x)

Neutrophilic activity was present in 78 (77.2%) out of the total 101 biopsies of chronic gastritis. The grading of neutrophilic activity was mild in 61 (78.2%), moderate in 15 (19.23%) and severe neutrophilic activity was seen in only 2 (2.56%) biopsies with chronic gastritis (Table 1). In 73 (93.58) biopsies presence of both neutrophilic activity and *H. pylori* was noted (Table 2). This association of presence of neutrophilic activity and *H. pylori* was highly significant (p value - 4.826×10^{-12}) (Fig. 2).

Lymphoid aggregate was seen in 23 (22.7%) biopsies of which four cases were associated with formation of lymphoid follicle. All the biopsies showing presence of lymphoid aggregate were associated with *H. pylori* in 23 cases (100%) (Table 2) thus, highly significant association of presence of lymphoid aggregate with *H. pylori* (p value - 0.0095) was noted (Fig. 3).

Atrophy was noted in 17 (16.83%) biopsies of which 15 (88.24%) biopsies showed mild atrophy and 2 (11.76%) biopsies showed moderate degree of atrophy, marked atrophy was not seen in any of the chronic gastritis biopsies (Table 1). Atrophy and presence of *H. pylori* was noted in 14 (82.35%) cases (Table 2) and the association was not significant using the Fischer exact test (p value- 1)

Malignancy features were seen in three biopsies. Of which two biopsies showed diffuse type of adenocarcinoma and one biopsy showed signet ring cell type of carcinoma. All the three cases of malignancy were not associated with *H. pylori* positivity.

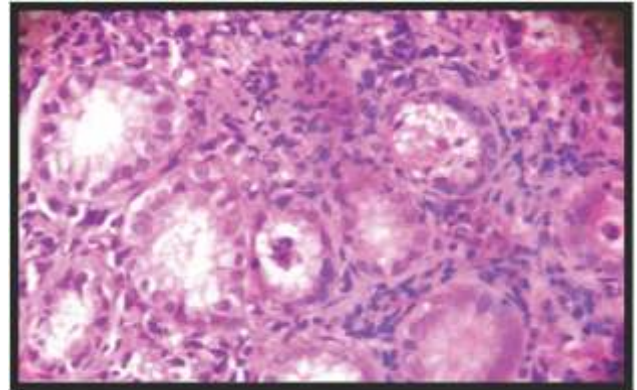


Fig. 2: Neutrophilic Activity H&E Stain (40x)

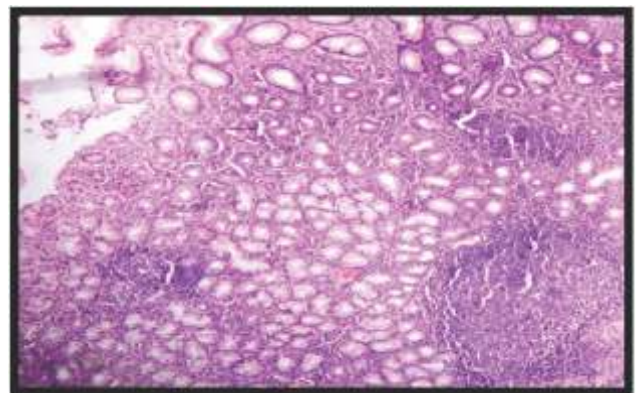


Fig. 3: Lymphoid Follicle H&E Stain (10x)

Discussion

H. pylori contributes to gastro-duodenal injury by impairing local mucosal defense. This is caused by a very high urease activity which causes rapid hydrolysis of urea at intercellular junctions resulting in alteration in the milieu of the gastric epithelium preventing the normal passage of hydrogen ions from the gastric glands through the

mucosa to the lumen and instead permits back diffusion. A consequence of back-diffusion is hypochlorhydria and a predisposition to ulcer formation [4].

The organism does not invade the tissue but lies within the protective mucosal lining of the stomach. Within the mucosal layer *H. pylori* produces urease which assists in its survival. The urease breaks down the urea present in gastric juices into bicarbonate, carbon dioxide and ammonia. Carbon dioxide and ammonia causes belching and reflux. Ammonia neutralizes the gastric acids allowing the organism to survive [5]. Individuals infected with *H. pylori* strains that secrete Vac A are more likely to develop peptic ulcers than people infected with strains that do not secrete this toxin [1]. Infection with vacuolating cytotoxin positive strains is reported to be associated with particular gastroduodenal diseases and was found to be more prevalent in isolates of *H. pylori* from individuals with peptic ulcer disease than those with gastritis. This offers a potential explanation as to why only a small percentage of persons infected with the organism, develop gastro-duodenal ulcer [6]. Strains that produce Cag A protein are associated with greater risk of development of gastric carcinoma and peptic ulcer [1].

Etiology of gastric cancer is multifactorial, most commonly it develops after a long period of atrophic gastritis [7]. Intestinal type of adenocarcinoma proceeds in a multistep manner and it starts from the condition of chronic active gastritis, followed by glandular atrophy, intestinal metaplasia, dysplasia and finally gastric adenocarcinoma [8]. Three translocation are associated with gastric MALToma, the t(11;18) (q21;q21), t(1;14)(p22;q32) and t(14;18) (q32;q21) [9].

In the present study, grading of chronic gastritis showed mild grade in 42.57%, moderate in

46.54% and marked in 10.90% biopsies. These findings are slightly different from Mysorekar *et al.* who showed mild grade of chronic inflammation in 52.84%, moderate in 40.46% and marked in 6.68% cases [10], however quite similar to Suzana *et al.*, who reported grade of chronic inflammation was mild in 47.4%, moderate in 40.90% and marked in 11.7% [1]. Neutrophilic activity of 77.2% is comparable to 73.38% of Suzana *et al.* [1].

Lymphoid aggregate of 22.7% in the present study appears to be slightly higher than Mysorekar *et al.* (30%) [10], quite higher than Suzana *et al.* (6.32%) [1]. However, atrophy in 16.83% biopsies appears to be quite similar to Suzana *et al.* (14.94%) [1], quite higher than Mysorekar *et al.*, who reported an atrophy of just 1.67% [10]. In the present study, *H. pylori* was seen in 78.2% biopsies, which fairly correlates with Kumar *et al.* who reported a prevalence rate 78% [11] and Mysorekar *et al.* who reported prevalence rate of 74% [10].

In 93.6% biopsies presence of neutrophilic activity was associated with *H. pylori* positivity. This association of presence of neutrophilic activity and *H. pylori* was highly significant (p value - 4.826×10^{-12}). This finding is slightly different from Kumar *et al.* who reported an association of *H. pylori* with neutrophilic activity in 83% cases [11].

In the present study all the biopsies showing presence of lymphoid aggregate were associated with the presence of *H. pylori* in 23 cases (100%), thus highly significant association of presence of lymphoid aggregate with *H. pylori* (p value - 0.0095) was noted. Mysorekar *et al.* showed significant association of *H. pylori* with lymphoid aggregate with germinal centre but the association was not significant between *H. pylori* and lymphoid aggregate without germinal centre [10]. Atrophy and presence of *H. pylori* was noted in 14

(82.35%) cases and the association was not significant using the Fischer exact test (p value - 1). Mysorekar *et al.* reported 5 cases of atrophy and all were associated with *H. pylori* but the association was not statistically significant [10].

Giemsa stain was used in this study as a special stain for *H. pylori*; this stain was found to be superior in *H. pylori* detection even when *H. pylori* were few in number. Also its cost effectiveness and ease of use makes it the best stain for *H. pylori* detection. It has been reported to be the best for *H. pylori* detection by Mysorekar *et al.* [10] and Kumar *et al.* also found it better than Warthin Starry stain and H & E stain [11].

Conclusion:

The results of present study indicate that *Helicobacter pylori* is strongly associated with chronic gastritis. Neutrophilic activity and presence of lymphoid aggregates in chronic gastritis cases was associated with *H. pylori* positivity, thus presence of these features can be taken as an indirect evidence of presence of *H. pylori*. It further indicates that finding of regional *H. pylori* prevalence and identifies high risk population infected with *H. pylori* helps to plan and implement treatment strategies in such patients to reduce complications associated with *H. pylori* infection.

References

1. Suzana MK, Skender T, Emine DD, *et al.* *Helicobacter pylori* gastritis Updated Sydney classification applied in our material. *Prilozi* 2009; 30: 45-60.
2. Glupczynski Y. Microbiological and serological diagnostic tests for *Helicobacter pylori*: an overview. *Br Med Bull* 1998; 54:175-186.
3. Bancroft JD and Gamble M. Theory and Practice of Histological Techniques, 6th ed. Philadelphia: Churchill – Livinstone, Elsevier; 2008.
4. Hazell S, Lee A. Campylobacter pylorides, urease, hydrogen ion back diffusion, and gastric ulcers. *The Lancet* 1986; 2(8497):15-7.
5. Wilkins S. *Helicobacter pylori*. Mikrograf, Spring 2008.
6. Maeda S, Ogura K, Yoshida H, *et al.* Major virulence factors, Vac A and Cag A, are commonly positive in *Helicobacter pylori* isolates in Japan. *Gut* 1998; 42:338-43.
7. Preiser F, Carneiro F, Correa P, *et al.* Gastric carcinoma. In: Hamilton SR, Altonen LA, editors. Pathology and genetics of tumors of the digestive system- World Health Organization Classification of Tumors; Lyon, France: IARC Press; 2000: 38-52.
8. Correa P. Human gastric carcinogenesis: a multistep and multifactorial process- First American Cancer Society Award Lecture on Cancer Epidemiology and Prevention. *Cancer Res* 1992; 52:6735-40.
9. Turner JR. The Gastrointestinal tract. In: Kumar V, Abbas AK, Fausto N, Aster J, editors. Pathologic basis of disease. 8th ed. Philadelphia: Elsevier, 2010: 763-832.
10. Mysorekar VVA, Chitralkha, Dandekar P, Prakash BSS. Antral histopathological changes in acid peptic disease associated with *Helicobacter pylori*. *Indian J Pathol Microbiol* 1999; 42:427-235.
11. Kumar A, Bansal R, Pathak VP, Kishor S, Arya PK. Histopathological changes in gastric mucosa colonized by *Helicobacter pylori*. *Indian J Pathol Microbiol* 2006; 49:352-6.

*Author for Correspondence: Dr. B. S. Nagoba, Assistant Dean (Research & Development), Maharashtra Institute of Medical Sciences & Research, Latur-413 531, Maharashtra, India
Email: dr_bsnagoba@yahoo.com, bsnagoba@gmail.com Cell: 9423075786